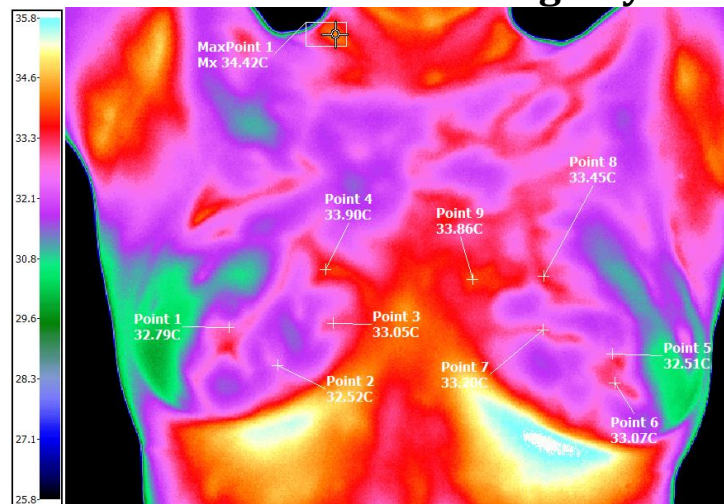


# ANALYSIS OF BREAST THERMOLOGY

Sample Patient, DOB: Date of Birth

Scan ID: Scan ID for Referring Physician



Study Date Frontal Thorax

**BACKGROUND:** Two (2) replicate sets of three (3) high-resolution radiometric infrared images were made of the anterior and the right and left lateral aspects of the thorax to feature the breasts. The second set of images was made immediately after the patient withdrew both hands from a one-minute immersion in cold (approx. 11°C) water. This procedure is a deliberate and simple dynamic functional challenge that anticipates the adaptive constriction of normal blood vessels with consequent cooling of the skin. The challenge is intended to differentially indicate regions of unregulated hyperemia that are reliably and proximally associated with solid cancerous neoplasm. The results of this challenge are coupled with specific features of vascular configuration, quantitative thermal differentials and, when available, time-based evolution of thermal patterns and levels to provide a multi-parametric risk assessment for breast cancer. The patient's related history includes a familial and two (2) personal risk factor(s) for breast cancer. The patient's related history includes no symptom(s) associated with breast disease.

Study Date(s)	Right Breast TH Score	Left Breast TH Score
Study Date	TH-2	TH-2
None		

**ANALYSIS:** The infrared images of the right and left breasts demonstrate essentially symmetric, distinct, large-caliber, hyperthermic and vascular-like patterns in the peri-areolar area (please refer to the Study Date Frontal Thorax thermogram above for specific features locations). None of the vascular-like patterns demonstrate asymmetric complexity. No significantly hyperthermic (+2.0°CΔ) and asymmetric foci or vascular-like patterns, asymmetric global emission levels, asymmetric complex vascular-like patterns or asymmetric physical distortions are discerned from the right or left breast. The post-challenge images demonstrate symmetric and adaptive attenuation of the emission levels from all of the thermal features of the right and left breasts.

**RISK ASSESSMENT:** Quantitative analysis of the infrared images does **not** indicate any thermology signs or criteria that establish risk for breast cancer of the right or left breasts. However, the hyperthermic and vascular-like patterns are consistent with estrogen-promoted benign glandular hyperplasia and related moderate to high tissue density of the right and left breasts.

**SUMMARY:** Benign-type atypical thermology; graded TH-2 for the right breast and TH-2 for the left breast. We recommend annual thermology for comparative analysis. ©Copyright 2001-2017. This report format, its text and image color pallet are copyrighted and may not be duplicated or replicated in any manner. All Rights Strictly Reserved. Therma-Scan Reference Laboratory, LLC. 34100 Woodward Ave. Suite 100 Birmingham, MI 48009 USA. +248.593.8700 <http://thermascan.com>



## About Breast Thermology

Medical Infrared Imaging obtains highly detailed and sensitive infrared images of the human body. Thermology is the diagnostic analysis of those images by a Board-Certified medical specialist by use of objective and quantitative methods derived from extensive medical science and sixty years of clinical development. Thermology (thermography) is listed by the US Dept. Health and Human Services as an adjunctive diagnostic modality for pathology of the female breast. Thermology evaluates tissue function and is distinctly different from tissue structure modalities, such as mammography, MRI and ultrasound. Thermology does not replace other diagnostic modalities but rather, they add to its diagnostic power and complement it as part of a comprehensive program of screening. Thermology is especially useful in instances where the diagnostic power of mammography is compromised; such as women that are pre-menopausal, have used hormone replacement therapy (HRT), have glandular or dense breasts, have fibrocystic disease, had prior biopsies, have implants or had breast reductions, are pregnant or nursing or have small or large breasts. Thermology has a very high (approx. 95%) sensitivity for the detection of breast cancer.<sup>1,2</sup> However, the specificity of thermology is compromised by tissue inflammation, infection, hormone imbalances of certain rare types of blood vessel abnormalities. The presence of these conditions may cause false-positive conclusions, especially on initial studies of an individual. Over time and with repeated studies, a questionable thermology feature will either resolve, demonstrate stability or evolve to reveal features distinctive of breast cancer. False-negative errors are rare and usually a consequence of an indolent (latent, non-growing) stage in the development of breast cancer. Masses, physical distortions and recent development of skin thickening, rashes or discharge from the nipple require further evaluation regardless of the thermology results.

## About the Scoring System

In 1972, a group of physicians and medical scientists at the renowned Pasteur Institute in Marseilles, France established an objective scoring system for breast thermology. This system provides for TH-1 through TH-5 scores based on specific thermology features, termed Signs and Criteria, to indicate a statistical risk for breast cancer.<sup>3</sup> The Marseille System was validated in a 1975 large-scale clinical outcomes study and is the international standard by convention.<sup>4</sup> The Marseille System long predates the American College of Radiology's BI-RADS<sup>®</sup> scoring system but is similar in concept and provides parallel indications.

## Understanding This Report

The TH-2 score defined a **qualified normal** result with moderate levels of thermal energy from regularly configured blood vessels that are symmetrically distributed in both breasts and respond normally to the functions (cold) challenge. The TH-2 score is frequently associated with benign (non-cancerous) conditions, such as hormone imbalances and dense tissue. The TH-2 score does not indicate breast cancer but it does not rule-out all possibility of breast cancer. Any concerning physical symptoms (i.e. new masses, skin discoloration or physical distortion) should not be ignored and other means of routine evaluation should not be neglected.

Ongoing breast care is a valuable part of an overall health maintenance program and should include the review of breast thermology reports by primary care and specialist physicians. Healthcare professionals may obtain more information on breast thermology by reviewing the PROFESSIONAL section of <http://thermascan.com> website or contacting our knowledgeable staff.

©Copyright 2001-2017. This report format, its text and image color pallet are copyrighted and may not be duplicated or replicated in any manner. All Rights Strictly Reserved. Therma-Scan Reference Laboratory, LLC. 34100 Woodward Ave. Suite 100 Birmingham, MI 48009 USA. +248.593.8700 <http://thermascan.com>

1. Parisky YR, et al. Efficacy of computerized infrared imaging analysis to evaluate mammographically suspicious lesions. Am J Roentgenol Radium Ther Nuci Med 2003;180.1:263-269
2. Hoekstra P. The autonomic challenge and analytic breast thermology. Thermology International 2003;14.3:106
3. Amalric R, et al. Les images thermovisuelles des cancers du sein et leur classifications. Corse Méditerranée Médicale 1972;216:13-22
4. Amalric R, et al. Value and interest of dynamic telethermography in detection of breast cancer. ACTA Thermographica 1976;1.2:89-96